



# Restoration of upper central incisors

Author: Paul Gerrard

CPD: 1 hour

## *Educational aims and objectives*

The aim is to show the reader with step-by-step illustrations a different technique for providing aesthetic zone prosthetics.

## *Anticipated outcomes*

The technician will have the knowledge to attack aesthetic solutions on upper incisors with added confidence.

This article is published by FMC. The publisher's written consent must be obtained before any part of this article may be reproduced in any form whatsoever, including photocopies and information retrieval systems.

While every care has been taken in the preparation of this article, the publisher cannot be held responsible for the accuracy of the information printed herein, or any consequence arising from it. The views expressed herein are those of the author(s) and not necessarily the opinion of the publisher.

# Restoration of upper central incisors

Paul Gerrard presents a detailed case study of this aesthetic zone treatment

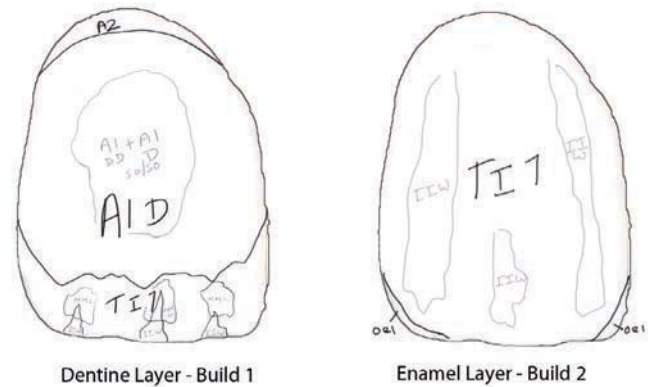


Figure 1: A copy of the lab prescription

Figure 2: A copy of the shading diagram



Paul Gerrard started his career at his father's dental laboratory in London in 1991 and, while carrying out his initial study at Lambeth College, he spent the next several

years learning the fundamentals of dental technology, gaining a broad range of experience.

In 2002 Paul attended the Las Vegas Institute to study anterior aesthetics and smile design, where his eyes were opened to the possibilities of full-mouth cosmetic restoration, and from where his passion for dental ceramics grew.

By 2005 Paul's brother Dr Neil Gerrard, who ran his own private practice in Bristol, had decided to begin the BACD accreditation process, and this led Paul to move to Bristol in 2008 and start a laboratory onsite at the practice. This allowed him to begin the process for technical accreditation and offer the highest levels of dental care.

Paul continues to develop his skills by attending courses and meetings throughout the UK, Europe and America, while working with likeminded clients who have an interest and passion in cosmetic and implant-based restorative dentistry.

For more information about the British Academy of Cosmetic Dentistry please visit [www.bacd.com](http://www.bacd.com) or email [info@bacd.com](mailto:info@bacd.com).

## INTRODUCTION AND PATIENT'S CHIEF COMPLAINT

The patient presented to the practice wishing to enhance the appearance of her smile after her upper central incisors had been traumatised two years ago, leaving them fractured and discoloured.

## SUMMARY OF CLINICAL INFORMATION: MEDICAL AND DENTAL HISTORY, DIAGNOSIS, TREATMENT PLAN AND TREATMENT CARRIED OUT

Trauma of the patient's central incisors had resulted in de-vitalisation and severe discolouring of the UL1 and an incisal fracture of the UR1, which was vital but had approximately 40% of the coronal tooth tissue missing. The UL1 had also been palatally displaced by about 1.5 to 2mm. UL1 had already been root treated and further radiographic examination indicated a potential periapical lesion, although the tooth was asymptomatic. Remaining dentition was healthy.

The aim of treatment was to restore correct form to the UR1 and bring UL1 labially in line with the existing UR1 and UL2, while restoring a more natural colour. It was decided that a full all-ceramic crown would replace UR1 due to the extent of the fracture with a veneer on UL1, which would allow correction of any form, position and shade issues and satisfy the

patient's wish for a more aesthetically pleasing smile. The patient was also instructed that UL1 would need further root treatment for long-term health and stability, but as the patient only had a two-week window to complete treatment, we were unable to carry it out at that point.

## DESCRIPTION OF PREP DESIGN

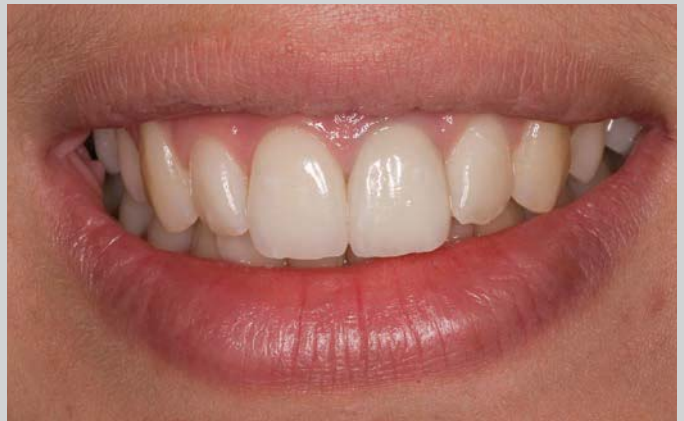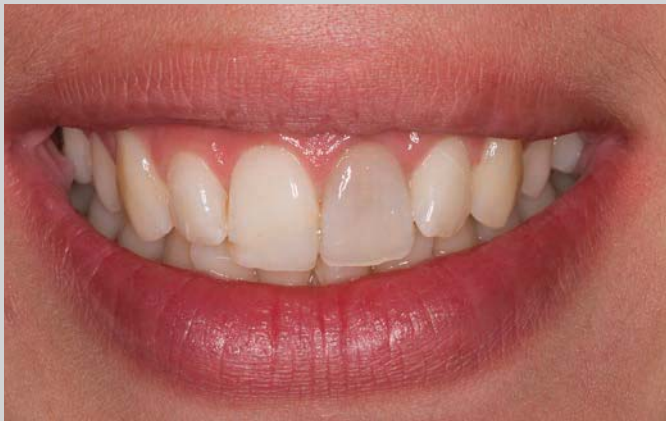Design follows the manufacturer's recommendation for all ceramic restorations, with an additional consideration for the CAD/CAM system used for frame production.

An incisal reduction of 1.5-2mm, including smooth round edges to avoid stress points and aid internal milling and fit, with a bevelled margin for ceramic support and optimum frame thickness in this area. As UL1 had been palatally displaced, only minimum reduction was required. The stump of the UR1 veneer was quite dark so a labial reduction of 1mm was made in the incisal region with an increased reduction of 2mm made in the upper cervical half, which would accommodate greater material thickness in the restoration for colour masking.

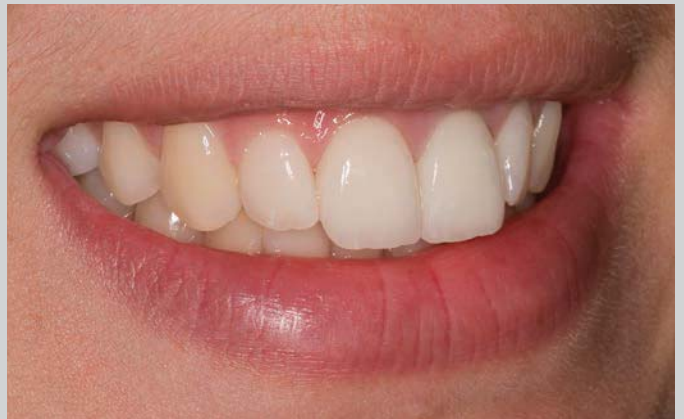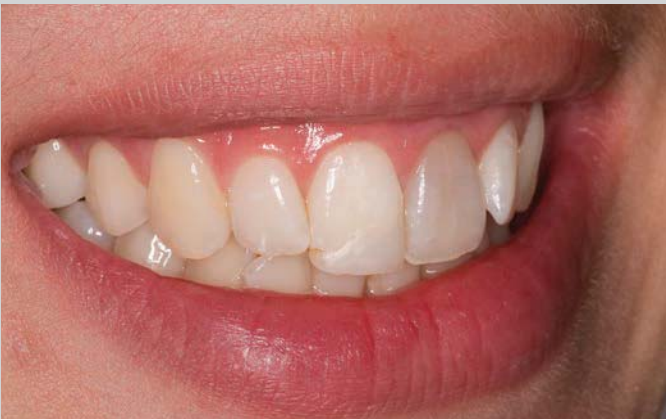Preparation design of UL1 also took into account access for re-treatment of endodontic orthograde root filling at a later date. A copy of the lab prescription, including shading diagram, can be seen in Figures 1-2.



Figures 3-4: Full face views, before and after



Figures 5-6: Smile views, anterior, before and after



Figures 7-8: Smile views, right, before and after

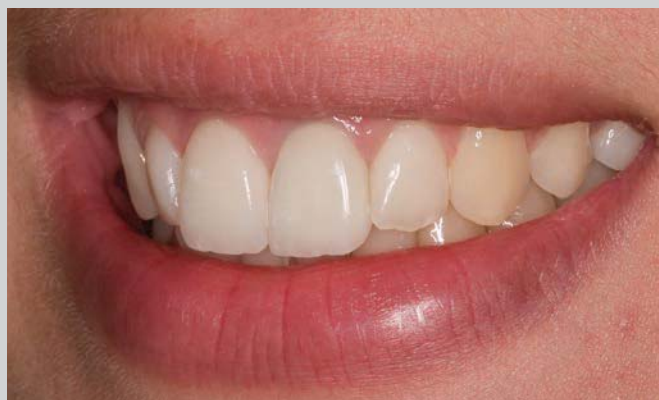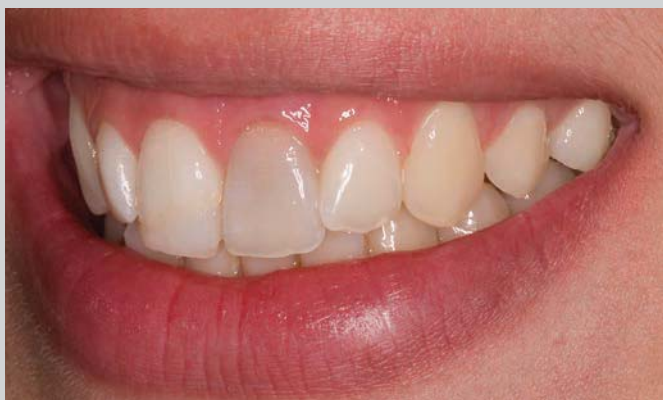**DISCUSSION OF MATERIAL CHOSEN AND REASON FOR CHOOSING IT**

Ivoclar IPS Emax CAD was the material of choice for this case, which has a wide range of indications including crowns,

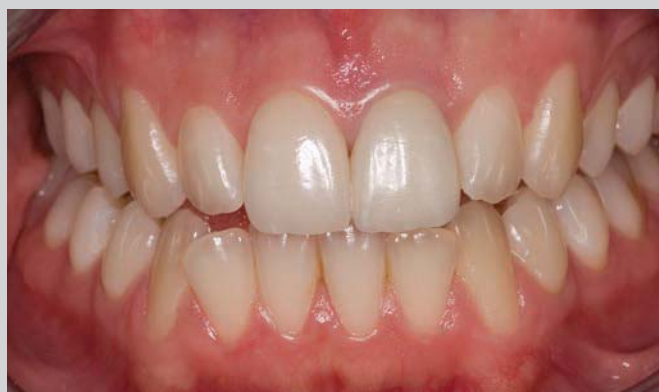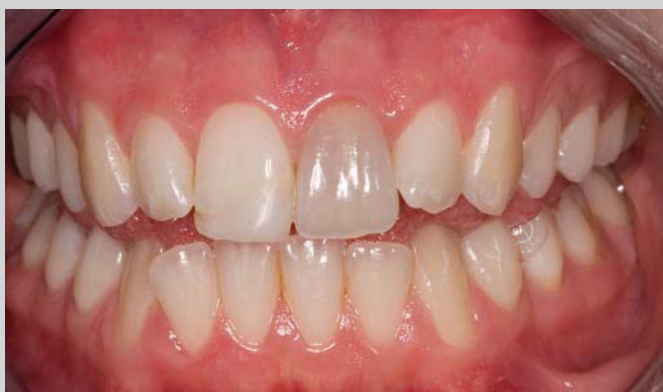bridges and veneers. e.max has a range of opacity levels and the ability to work to very thin sections (0.3mm) thanks to its strength of 360-400mpa. In my opinion this makes Emax the most flexible, durable and aesthetically pleasing product

currently available for anterior restoration. As the patient's stump shade on tooth UL1 was quite dark, a medium opacity block (MO1) was chosen. This would be sufficient to mask the underlying colour and achieve a final shade in the region of

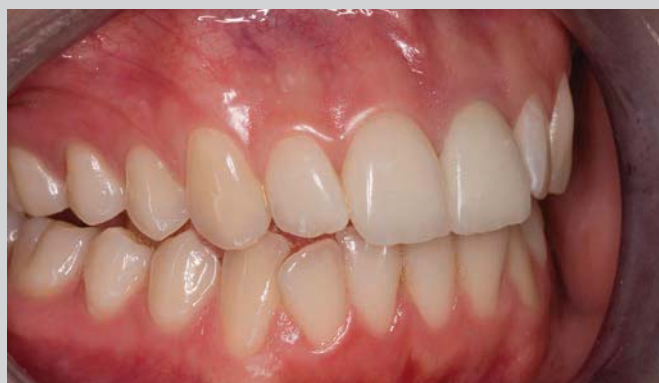
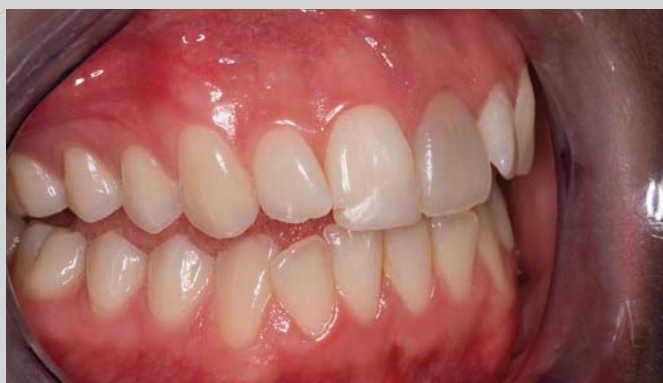


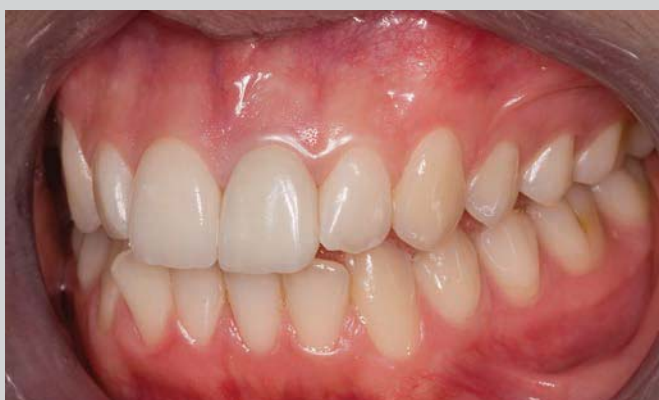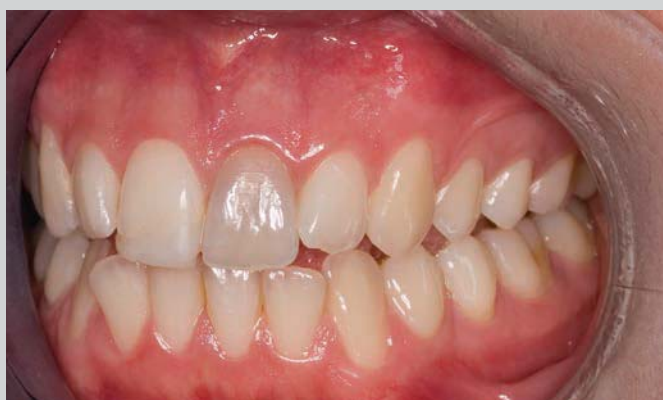Figures 9-10: Smile views, left, before and after



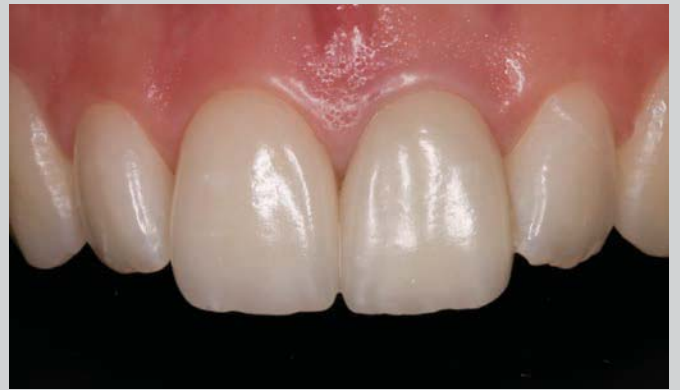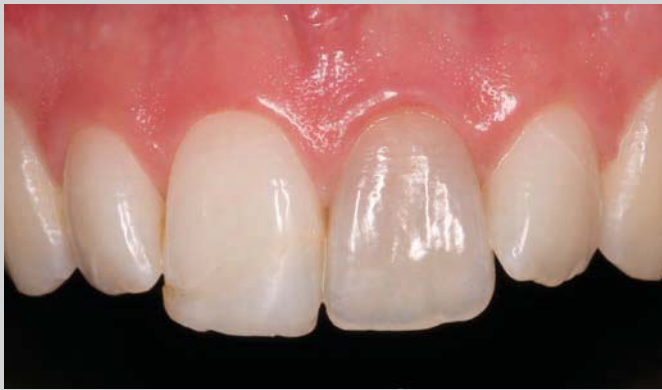Figures 11-12: Retracted views, anterior, before and after



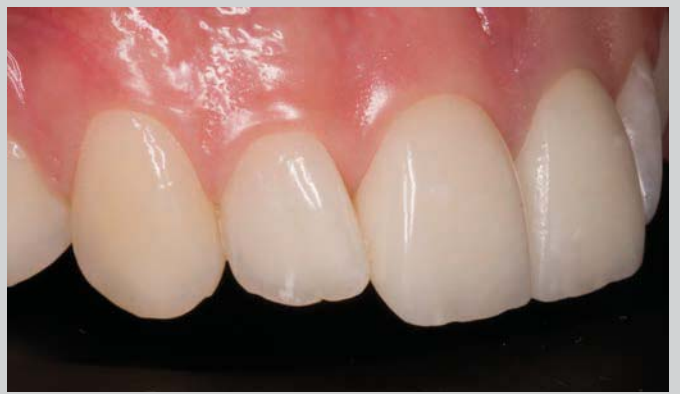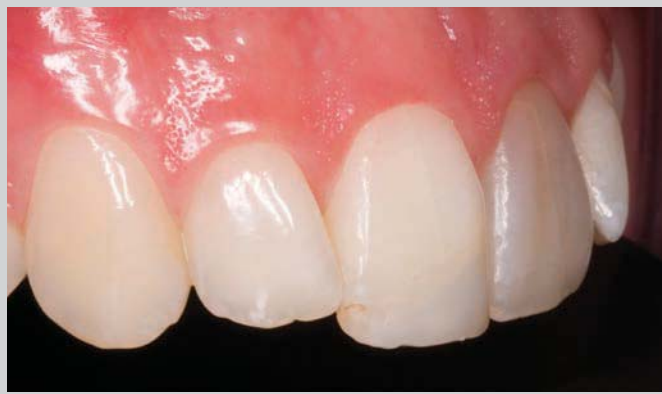Figures 13-14: Retracted views, right, before and after



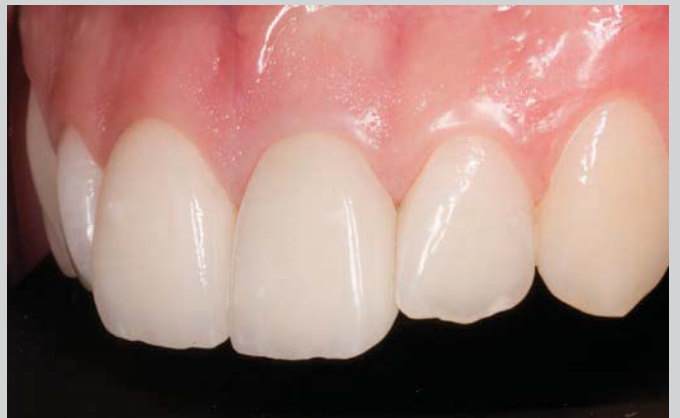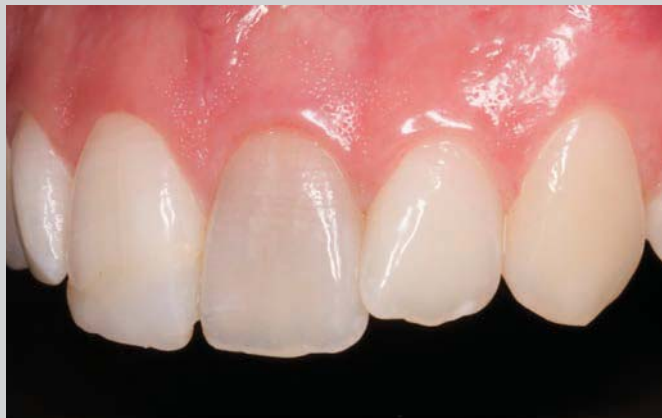Figures 15-16: Retracted views, left, before and after



Figures 17-18: Views, anterior, before and after



Figures 19-20: Views, right, before and after



Figures 21-22: Views, left, before and after

A1. The same block was also used for UR1 to help maintain a uniform colour between the two restorations.

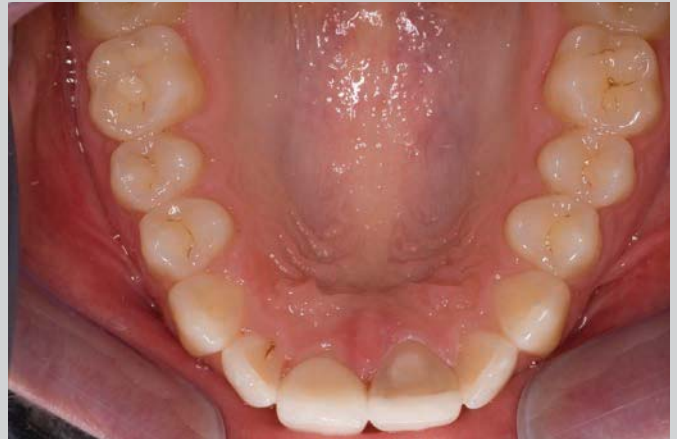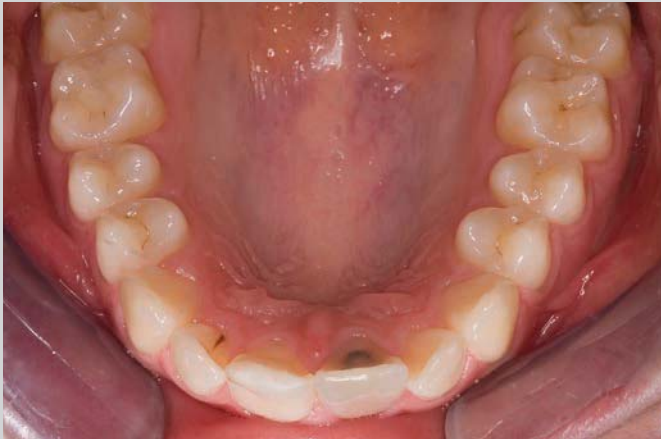### DESCRIPTION OF PRODUCTION OF MODEL

The impression was first sprayed with a wetting agent to aid the flow of die stone and help reduce bubble formation. The type 4 die stone Fujirock EP Optixscan was chosen for its low expansion, strength and scanning properties, which aid accuracy during the CAD/CAM fabrication of the

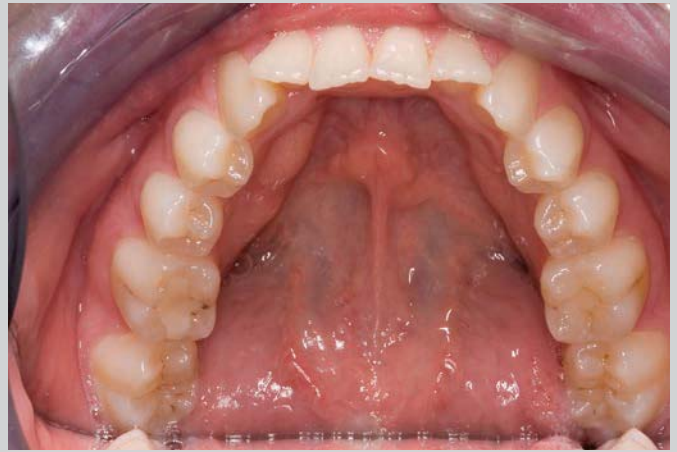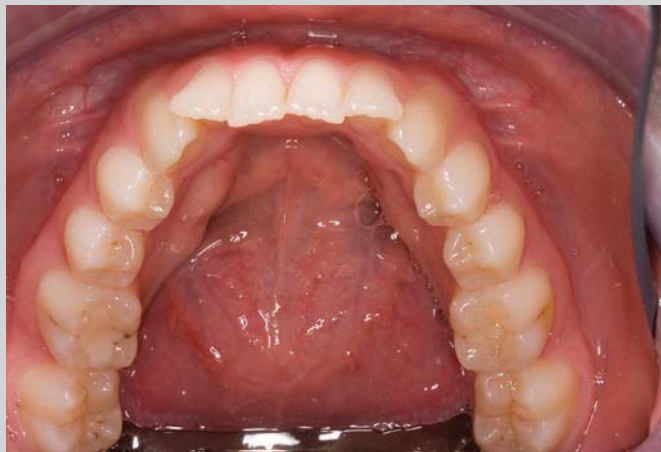framework. The die stone was mixed under 3.5 bar vacuum for 40 seconds, then poured into the impression to a sufficient thickness to allow removal of the cast without breakage. This was allowed to set for one hour. The cast was then removed and trimmed on a dry trimmer to avoid any additional wetting and expansion of the stone. To construct the sectioned model, holes were drilled with an Aman Ppindex unit. A small amount of glue was applied to the pins from the crosspin system, which were then placed into the holes

and sprayed with an activator to set the glue. The base was then sprayed with a separating agent and plastic sleeves were placed over the pins. The plastic base from the crosspin system was then filled with die stone and a small amount of die stone was placed around each sleeve to stop any air pockets forming around them, before seating the model into the base. This was then allowed to set for a further hour before removal. The two parts were then separated and the cast impression was sectioned with a Pindex saw to allow





Figures 23-24: Upper occlusal views, before and after



Figures 25-26: Lower occlusal views, before and after

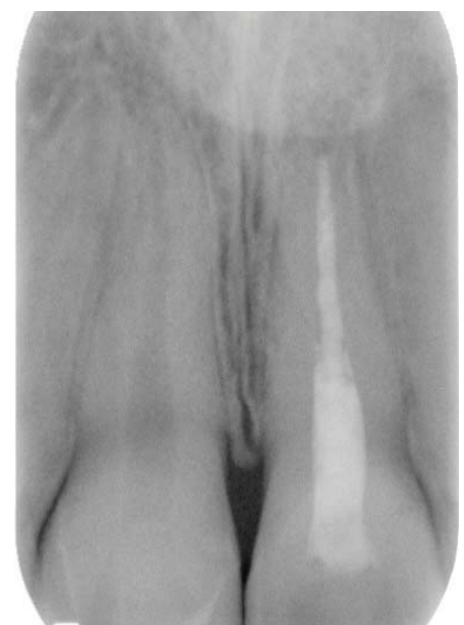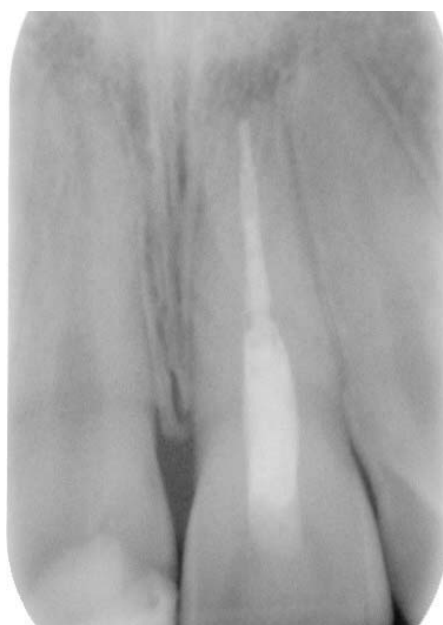removal of the working dies. An additional solid cast was also made using Fujirock EP, which would be used for verification of contacts and tissue contour.

### DESCRIPTION OF DESIGN AND PRODUCTION OF FRAME WORK

The model die was first trimmed and ditched under x6 magnification to ensure integrity of the margin and allow easy identification of the margin by the Cerec Inlab CAD software to be used. Sectional cuts in the model were filled with scanning putty to avoid any anomalies in the proceeding scan.

The model was mounted on the Sirona Ineos scanning platform and sufficient images were taken to ensure an accurate 3D model.

A scan was then taken of the provisional model, which could be superimposed over the preparation model and aid in design of the frames. Margins were defined in the software and frames were designed



Figures 27-28: Radiographs, before and after

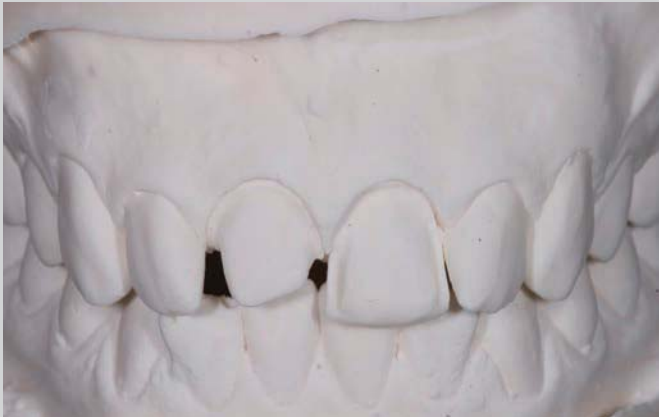

Figure 29: Frontal view of models articulated

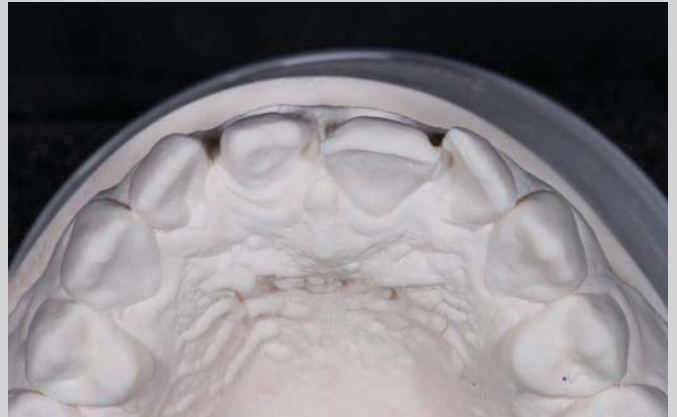

Figure 30: Occlusal view of model

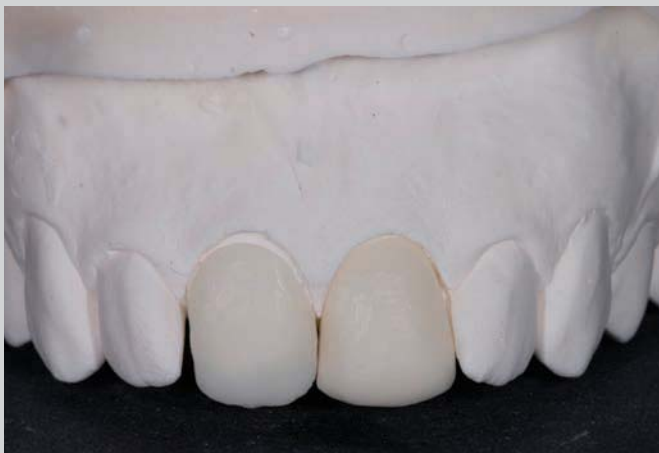

Figure 31: Frontal view of framework

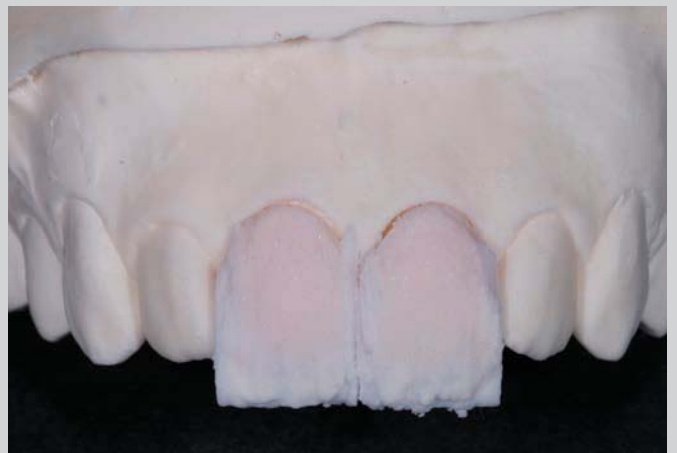

Figure 32: Frontal view of build-up 1

to approximately 80% of the size of the provisional restorations. These were then milled from an Emax MO1 block via the MCXL milling unit. After approximately 10 minutes the completed frames were removed from the milling chamber and the fit was checked on dies with blue marker under magnification.

It was then necessary to sinter the frames which transform them from their blue lithium metasilicate phase into the final lithium disilicate state, achieving their final shade and strength.

The frames were filled with object fix putty, which supports them during the sintering processes, and placed onto the sintering tray. A 45-minute sintering cycle was then conducted at 850 degrees before allowing the frames to cool to room temperature. The fit was checked again on the dies and the margins were then thinned out to create a smooth emergence profile.

### DESCRIPTION OF LAYERING OF CERAMIC

A base shade of A1 was chosen with a slight A2 neck. This was slightly brighter than the laterals to create the illusion of dominance in the central region and aid the three-dimensional appearance of the arch. A putty incisal index was fabricated against the provisional model which the working model could be seated into. This would then provide a template for the incisal form of the build up. The frames were first moistened with glaze liquid and dusted with a fine layer of A1 deep dentine which was then fired on a regular dentine cycle but with a slower climb rate, which allows the particle sizes of the ceramic to mature more slowly and create an optimal bond to the frames. Without this layer, any additional layers run the risk of cracking or delamination. The grainy surface also helps to refract light as it passes through the ceramic. A thin wash of

stain was then applied to the frames and fixed with a low temperature firing cycle, which gave the frames the desired shade.

A thin band of A2 dentine was applied to the cervical third and a mixture of A1 deep dentine and A1 dentine was applied to the mid region to increase chroma slightly and help mask the underlying stump colour. A1 dentine was used to cover the rest of the frames. Translucent Incisal 1 was placed at the mesial and distal sides of each unit and also along the incisal edged, approximately 1mm longer than the incisal index to allow for shrinkage. Some small wedges were removed from the incisal edge, which were filled with Inter Incisal white (IIW), and some mammelons were created with MM Light, which would break up the monochromatic appearance of the incisal edge. The restorations were then fired. On the second build, IIW was used to highlight the mesial and distal line angles and OE1,

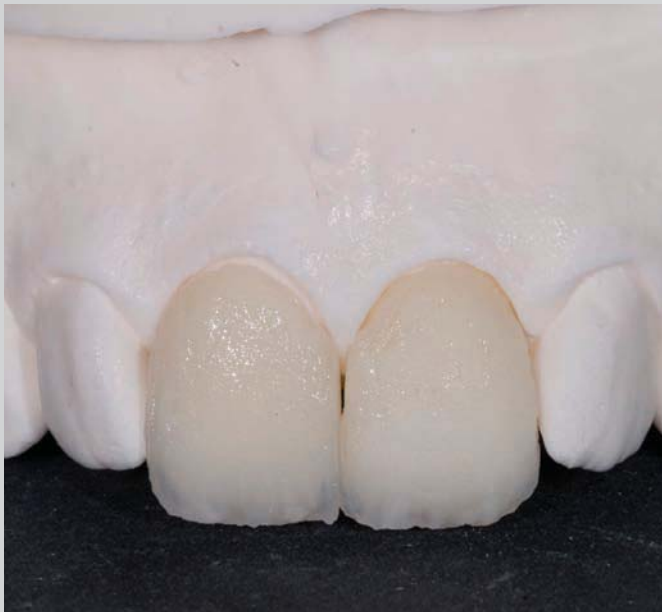

Figure 33: Frontal view of bisque bake 1

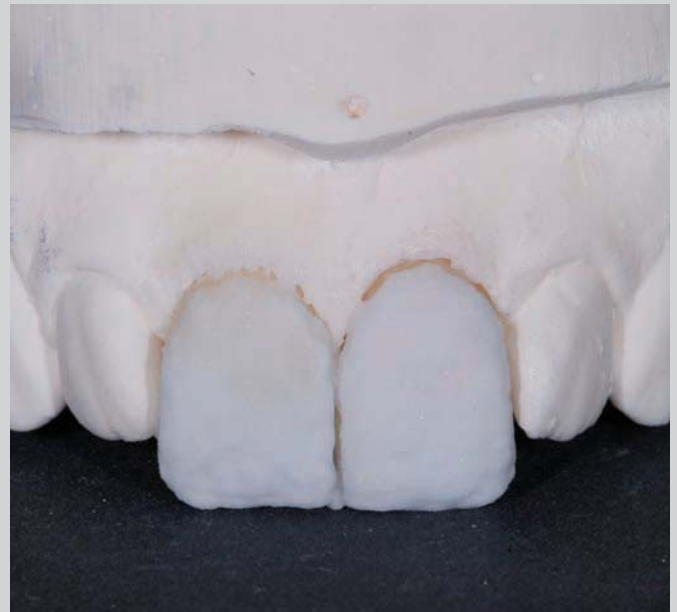

Figure 34: Frontal view of build-up 2

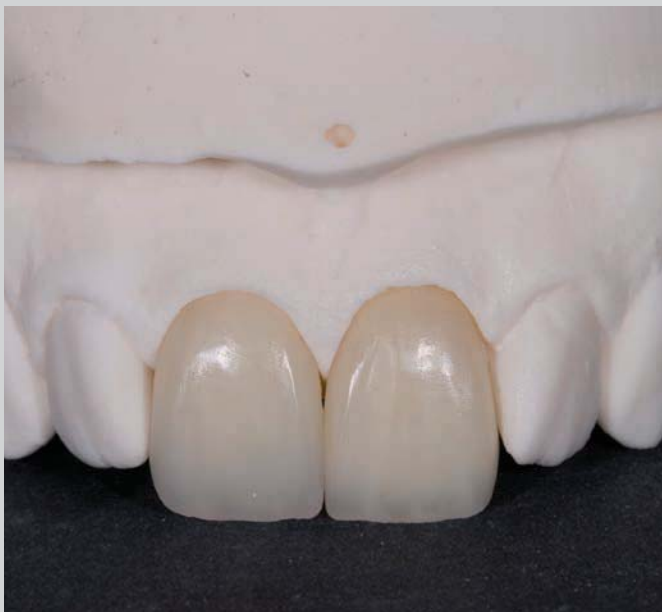

Figure 35: Frontal view of bisque bake 2

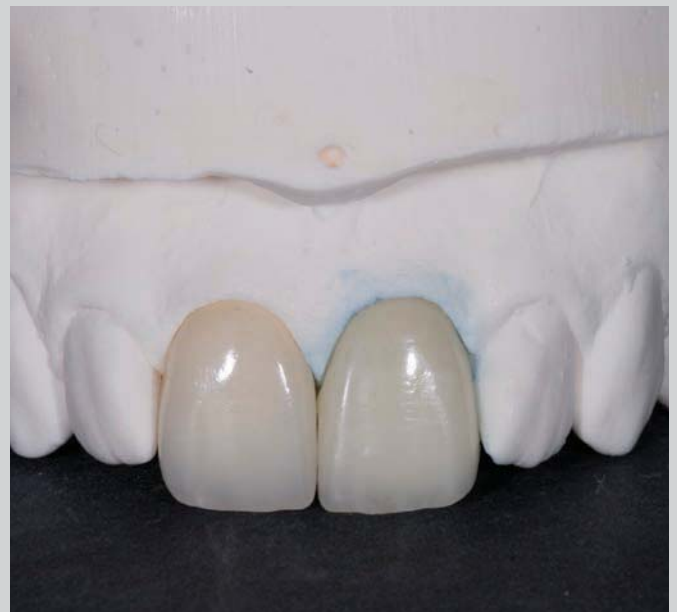

Figure 36: View of completed case on model

a blue opalescent enamel, was used on the incisal corners. The whole surface was then covered in a thin layer of T11. Mesial and distal edges were built out slightly to allow precise modification of contacts. A second firing cycle was then carried out with a slight temperature reduction to limit any further shrinkage of the previous layer. This two-stage build up technique allows greater control of shrinkage and modification of any internal effects before the final enamel layer is applied, thus avoiding a complete restart of the ceramics should the internal effects need intensifying or reducing.

Once the veneers were re-fitted to the solid model and any shape modifications made using the incisal index for reference, the surface was smoothed with a fine wet diamond and primary anatomy was created. A rubber wheel was then used to smooth the surface further and some fine secondary anatomy was added.

Some white/cream stain was then applied to create some small decalcification areas and this was fixed with a low fusing cycle, followed by application of glaze liquid and firing cycle to seal the surface of the ceramic.

## CONCLUSION

The restorations were then lightly buffed on a lave with a fine synthetic pumice to reduce plaque adhesion and achieve the final desired surface lustre. **CPD**

## REFERENCE

1. Petra Bühler-Zemp / Dr. Thomas Völkel - Scientific Documentation IPS e.max Press - March 2007